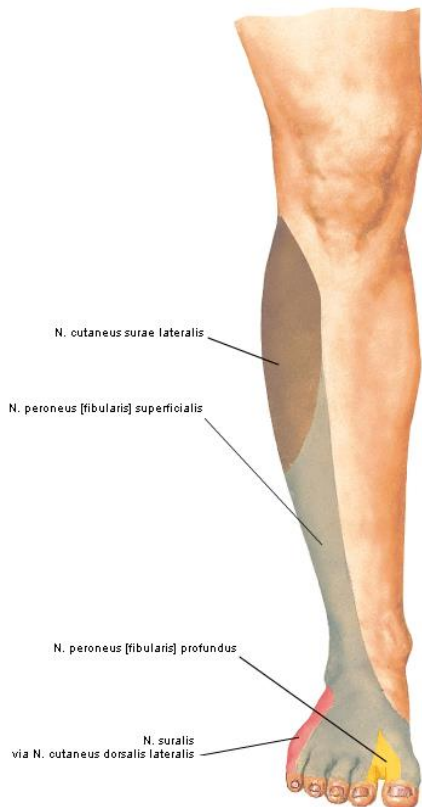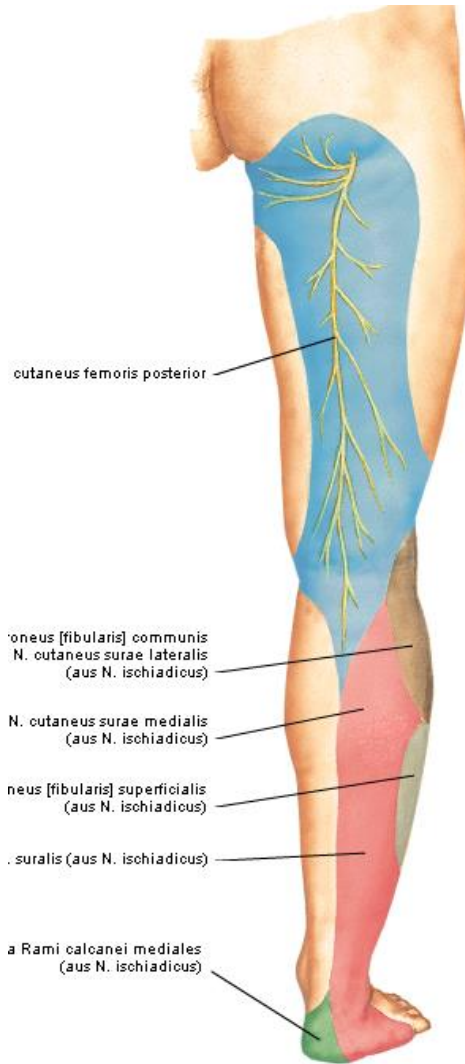
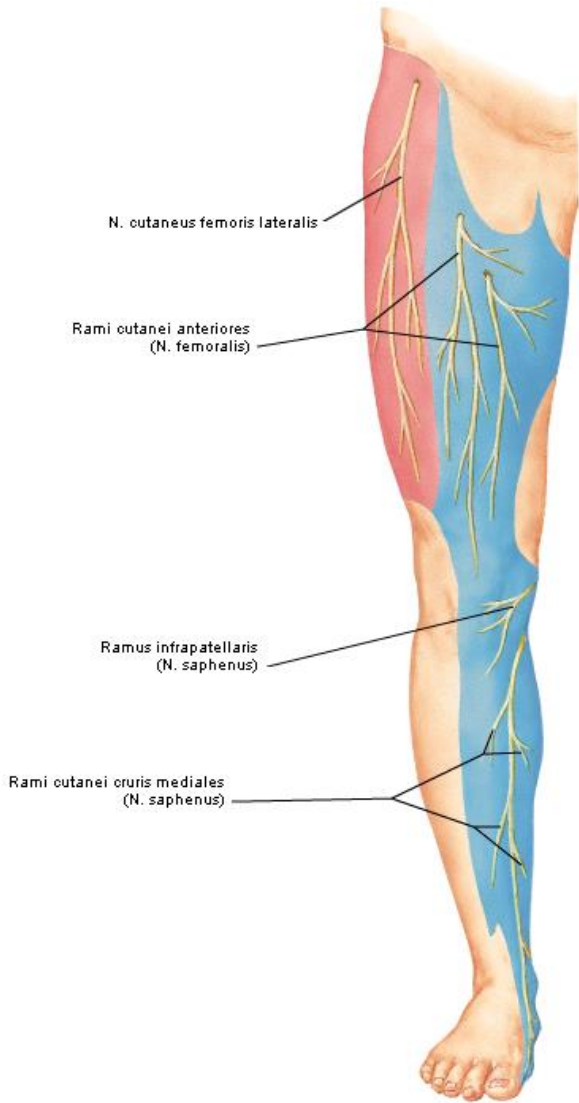
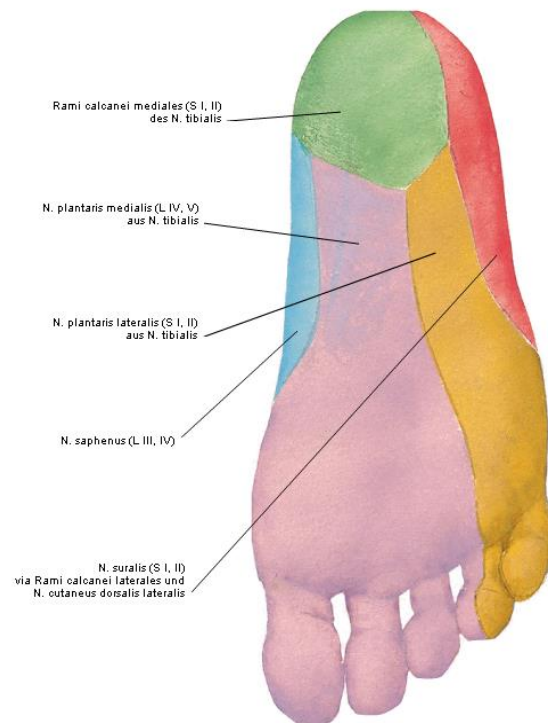


Nervenversorgung untere Extremität

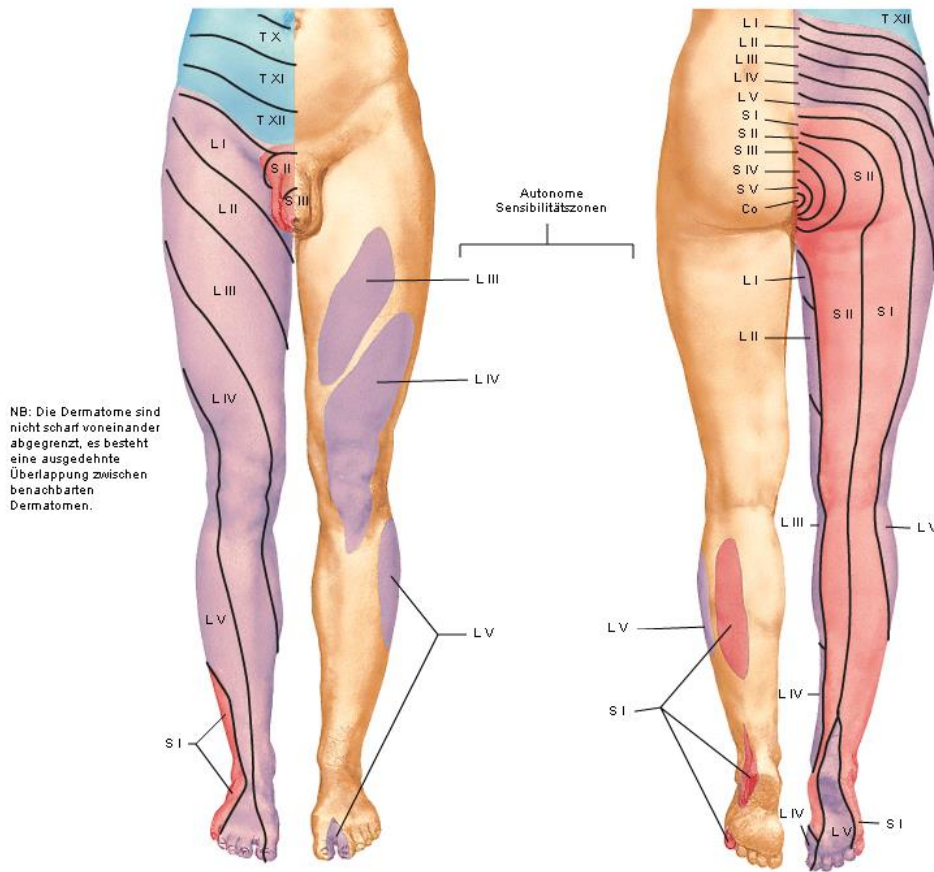


Nervus Tibialis Sensible Innervation der Fußsohle



Hautsegmente (Dermatome) der unteren Extremität

Ansichten von ventral und dorsal



Segmentale Innervation für die Bein- und Fußmotorik

